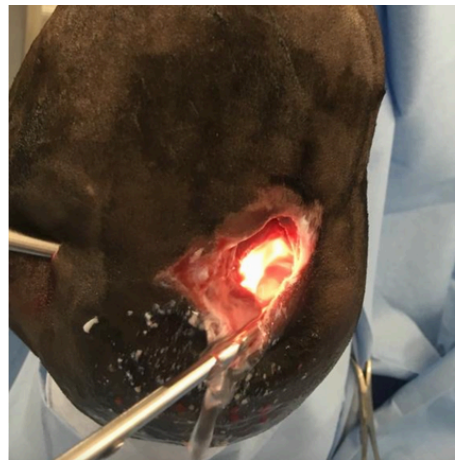


Joint infections and why understanding the basic anatomy of your horse is important

We all know how important it is to understand our own horse and what is 'normal' for them. This is one of the many reasons we are able to detect small things quickly, such as an unusual swelling, heat in a leg or a lameness. When it comes to problems such as joint infections it is also important to understand the basic anatomy of a horse so that we can pinpoint exactly where a joint is, which then allows us to make a more informed decision as to whether a wound is potentially an issue or not.

Joint infections are the most common cause of emergency surgeries at our clinic. One of the most important factors in a successful outcome is time, the quicker we can get a horse to surgery the better the prognosis, which is why it is important to understand the signs to look for.



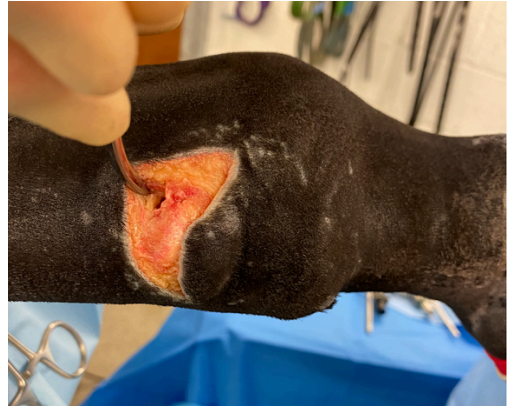Wounds

Wounds over the lower parts of the legs are very common and the lack of muscle covering these lower joints makes the horse more susceptible to damage. The thin joint and tendon sheath capsules that hold the fluid within both the joints and tendon sheaths are directly underneath the skin which means that they are more easily involved in a wound.

When a wound, (of any size, including puncture wounds), extends into a joint or tendon sheath there is a quick, irreversible deterioration within the joint that takes place. The joint fluid and environment provides the perfect environment for the bacteria, which then take up residence within the fluid and the lining of the joint capsule.

The horse's body tries to deal with this infection by producing more fluid to wash out the infection but more importantly a huge number of white blood cells are forced into this joint space to try and mop up the bacteria. Along with the white blood cells (neutrophils) there is also a whole cascade on different inflammatory enzymes which unfortunately also then damage the joint further.

These horses are usually abscess lame (except in cases of large wounds where the excess fluid drains out easily), and this is one of the important warning signs that we, as vets, will quickly take seriously - so giving a sachet of bute isn't necessarily a good thing to do before your vet has had a chance to examine your horse.



There will usually be a wound over the joint, many people think this will be a deep laceration, but even the smallest of punctures, such as a thorn, can cause an infection. There may be fluid coming out of the wound, joint fluid is straw coloured, so if this is present call your vet immediately.

What happens next?

If a joint infection is suspected your vet will usually take a sterile sample of joint fluid (a joint tap). The gross appearance of the joint sample can also give us a clue - it should be straw yellow and clear. When infected it becomes tan coloured and cloudy. You should be able to read a newspaper through the sample.

To be certain we also run the sample through our laboratory machines as well as making smear which we can look at under the microscope. When a joint or tendon sheath is infected - this is a genuine surgical condition, no amount of antibiotics alone will help a horse in this situation.

The success rates of the GA and surgery far outweighs that of just the needle flush under standing sedation. This is primarily because the surgery allows us to both flush through a large volume of fluid, often between 10 and 20 litres, but more importantly to look inside the joint.

It is very common to see hairs and dirt within the joint, stuck to the edges of the wound within the joint, as well as the inside of the joint capsule.

After flushing the whole of the joint we can then use antibiotics either within the joint or more commonly as an infusion surrounding it. The infection is considered successfully resolved when the horse remains comfortable at least 4-5 days after the initial surgery, and a subsequent joint sample has a normal white cell count when run through the lab machines again.

The key to successful treatment of joint infections is time - the quicker a horse is seen and is operated on the better the result. If this occurs within 6-8 hours of a wound happening we expect to send over 90% of patients home again having resolved the joint infection.



The vast majority of these horses will then be able to continue in the same levels of exercise again after a period of rehab. However when this period extends to over 12 and then 24 hours, it is often the case that a second surgery 2-3 days after the first as well as IVRAs are needed to try and treat the infection. If your horse has a cut, no matter how large or small, over a joint and is lame it is important to call your vet.

If you would like any additional information please call us on 01577 841010.