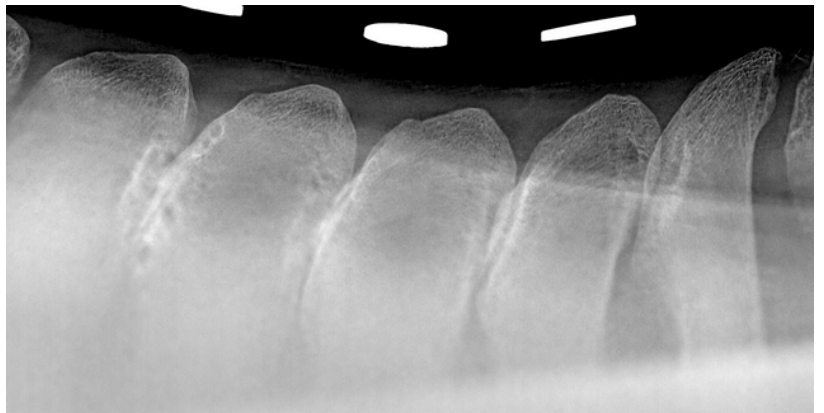


Kissing Spine

What are Kissing Spines?

Back pain is a common problem in the horse. However, it can be difficult to accurately pinpoint exactly where and what is causing the pain. It is far more common to have stiff and sore muscles than genuine bony pain. Secondary back pain (normally muscle pain) is usually seen due to poor fitting saddles, a low grade lameness causing a tense and restricted gait or lack of core strength and muscle tone.

Primary back pain associated with the bones of the back is more commonly referred to as 'Kissing Spines' – although there are other causes of bony back pain as well (eg articular facet or joint disease). There are long bony processes that stick up from the spinal column, the tips of which can be felt under the skin.



These are called the dorsal spinous processes (DSPs). Kissing Spines is a term used to describe pain arising from these DSPs and the ligament between them. The impingement can just be a narrowing of the space, through to contact between the DSPs, and finally the space is completely obliterated as the DSPs then overlap. There is usually considerable bony remodelling where the two adjacent DSPs are in contact.

Symptoms

Most horses will present with a history of resenting being tacked up, often being 'cold backed' when the saddle is placed, girthed up and when the rider first sits in the saddle. This can range from a very mild dipping of the back to full-blown bucking and galloping off.

Alternatively some horses may have a performance issue – finding it difficult to bascule properly when jumping, or lifting the top line to work in an outline.

The majority of horses will also have a weak top-line, with underdeveloped epaxial muscles (the longissimus dorsi muscle which the saddle sits on). A dipped back therefore results in further narrowing of the spaces between the DSPs, and thus a vicious cycle tends to develop.

Diagnosis

It can often be possible to differentiate between muscle pain and bony pain arising from kissing spines by very careful palpation – whilst a very painful or sensitive horse might guard its whole back, most horses will be more responsive to focal pressure directly on the midline over the bony prominences if kissing spines is a genuine problem.

An accurate diagnosis is important – as there are many horses who compete normally with a degree of bony remodelling that could be seen on an x-ray.

A routine evaluation would include a combination of clinical examination, x-rays of the bony processes (DSPs) along with assessing the response to either local anaesthetic between the DSPs or alternatively a clinical improvement to medication with a corticosteroid. It is normally important to assess this under saddle as well as in hand.



Treatment Options

In the majority of horses a combination of medication and rehabilitation / physiotherapy can be used to strengthen the top-line muscle, which has often wasted away to an extent. If this top-line strengthens and lifts the back up, the gap between the DSPs can open up again reducing the pain and halting the vicious cycle.

This physiotherapy and rehabilitation can't be successfully achieved on its own, because there has to be a reduction in pain and inflammation before it can fully work, as the horse will still be guarding and restricting the amount of extension of the spine. This is where the prior medication is important to allow us to then work together with the physiotherapists.

There are also other treatments available. 'Tildren' or 'Osphos' are drugs from the same family which can alter bony metabolism. It is now fairly routine to use one of these two medications in conjunction with steroid injections into the space between the DSPs.

Unfortunately there are also some cases that either do not respond well to medication, or alternatively that response is very short-lived. There are therefore further surgical options to treat these cases.

Historically the abnormal over-riding DSPs were surgically removed under a general anaesthetic. Removing such a large piece of bone resulted in a substantial hole under the skin that took some time to heal and then strengthen again. More recently this surgery was performed under a standing surgery instead.

This DSP removal is now usually kept in reserve though – because a minimally invasive technique is now routinely used to cut through the ligament between the DSPs. This is known as an interspinous ligament desmotomy (ISLD).

This has the advantage of being able to treat multiple sites at the same time, under standing sedation, without removing the large chunks of bone. The healing time is therefore considerably reduced (down to 2-3 months from 9-12), however it is still essential to strengthen the back again with physiotherapy and rehabilitation exercises.

The outlook for the majority of horses, even those requiring surgery, is favourable. However there are many cases whereby a concurrent lameness or pain elsewhere can also limit the future use of the horse.

If you would like any additional information please call us on 01577 841010.